



United States Multicenter Clinical Trial of Corneal Collagen Crosslinking for Keratoconus Treatment

Peter S. Hersh, MD,¹ R. Doyle Stulting, MD, PhD,² David Muller, PhD,³ Daniel S. Durrie, MD,⁴ Rajesh K. Rajpal, MD,^{3,5} on behalf of the United States Crosslinking Study Group*

Purpose: To evaluate the safety and efficacy of corneal collagen crosslinking (CXL) for the treatment of progressive keratoconus.

Design: Prospective, randomized, multicenter, controlled clinical trial.

Participants: Patients with progressive keratoconus (n = 205).

Methods: The treatment group underwent standard CXL and the sham control group received riboflavin alone without removal of the epithelium.

Main Outcome Measures: The primary efficacy criterion was the change over 1 year of topography-derived maximum keratometry value, comparing treatment with control group. Secondary outcomes evaluated were corrected distance visual acuity (CDVA), uncorrected distance visual acuity (UDVA), manifest refraction spherical equivalent, endothelial cell count, and adverse events.

Results: In the CXL treatment group, the maximum keratometry value decreased by 1.6 diopters (D) from baseline to 1 year, whereas keratoconus continued to progress in the control group. In the treatment group, the maximum keratometry value decreased by 2.0 D or more in 28 eyes (31.4%) and increased by 2.0 D or more in 5 eyes (5.6%). The CDVA improved by an average of 5.7 logarithm of the minimum angle of resolution (logMAR) units. Twenty-three eyes (27.7%) gained and 5 eyes lost (6.0%) 10 logMAR or more. The UDVA improved 4.4 logMAR. Corneal haze was the most frequently reported CXL-related adverse finding. There were no significant changes in endothelial cell count 1 year after treatment.

Conclusions: Corneal collagen crosslinking was effective in improving the maximum keratometry value, CDVA, and UCVA in eyes with progressive keratoconus 1 year after treatment, with an excellent safety profile. Corneal collagen crosslinking affords the keratoconic patient an important new option to decrease progression of this ectatic corneal process. *Ophthalmology* 2017;124:1259-1270 © 2017 by the American Academy of Ophthalmology

Over the past decade, corneal collagen crosslinking (CXL) has emerged as a promising technique to stop or slow the progression of keratoconus.¹⁻³ Corneal collagen crosslinking mitigates the keratoconus disease process by strengthening and stabilizing the collagen lamellae, mimicking the age-related crosslinking that occurs in the cornea over time.⁴ The treatment results in mechanical stiffening of the cornea, with the clinical goal being a consequent decrease in disease progression. We report herein the results of CXL for the treatment of progressive keratoconus in 205 participants enrolled in the United States phase III, multicenter, prospective, randomized, sham-controlled clinical trials of CXL over a 1-year post-operative period.

Methods

Patients were enrolled as part of 2 multicenter, prospective, randomized, sham-controlled clinical trials evaluating CXL with Photrexa Viscous (0.1% riboflavin ophthalmic solution plus 20%

dextran), Photrexa (0.1% riboflavin ophthalmic solution), and the KXL System (Avedro, Inc., Waltham MA). Two concurrent studies were performed based on guidelines of the United States Food and Drug Administration for premarket approval of a new drug (New Drug Application no. 203324) and were approved and monitored by an investigational review board (clinicaltrials.gov identifier, NCT00647699).⁵ The studies complied with the United States Health Insurance Portability and Accountability Act. All patients provided informed consent. Randomization was computer generated, and on the procedure day, a sealed envelope was opened by the investigator to reveal whether the eye would be in the control or treatment group. Both patients and investigators were aware of the randomly assigned group.

Inclusion criteria included age 14 years or older, an axial topography pattern consistent with keratoconus, maximum keratometry 47.0 diopters (D) or more on corneal topography (Pentacam; Oculus GmbH, Wetzlar, Germany), an inferior-to-superior ratio of more than 1.5 on topography mapping, corrected distance visual acuity (CDVA) worse than 20/20, corneal thickness 300 µm or more as measured using a Pentacam, and a diagnosis of progressive keratoconus. Progressive keratoconus or ectasia was defined as 1 or more of the following changes over a period of 24

months: an increase of 1.00 D or more in the steepest keratometry measurement, an increase of 1.00 D or more in manifest cylinder, or an increase of 0.50 D or more in manifest refraction spherical equivalent (MRSE). Exclusion criteria included patients with a history of corneal surgery, including intracorneal ring segments, corneal pachymetry less than 300 μm , and a history of corneal disease that would interfere with healing after the procedure, such as chemical injury or delayed epithelial healing in the past. Patients who were pregnant or lactating during the course of the study were excluded.

Corneal Collagen Crosslinking and Sham Control Treatments

Contact lens wearers were instructed to discontinue spherical soft lenses for a minimum of 3 days, and soft toric lenses and rigid gas-permeable lenses for a minimum of 2 weeks before the preoperative eye examination. Then they were required to show a stable refraction at 2 examinations that were at least 7 days apart. A stable refraction was determined as one in which the MRSE and maximum keratometry measurements at the first visit did not differ by more than 0.75 D from the respective measurements at the second visit.

Patients initially were randomized into a treatment or sham control group (Fig 1). The treatment group received standard ultraviolet A-riboflavin 0.1% CXL treatment, performed according the methodology described by Wollensak et al.³ Initially, a topical anesthetic agent was administered and the central 9.0 mm of epithelium was removed by mechanical debridement with a blunt spatula. Riboflavin (0.1% in 20% dextran T500 solution) then was administered topically every 2 minutes for 30 minutes. Riboflavin absorption throughout the corneal stroma and anterior chamber flare was confirmed by slit-lamp examination.

Ultrasound pachymetry was performed, and if the cornea was thinner than 400 μm , hypotonic riboflavin (0.1% riboflavin, no dextran) was administered 1 drop every 10 seconds for 2-minute sessions, after which ultrasound pachymetry was performed to ascertain that the stroma had swollen to more than 400 μm . This was repeated in 2-minute sessions until adequate corneal thickness was obtained. The cornea was aligned and exposed to ultraviolet A (365-nm) light for 30 minutes at an irradiance of 3.0 mW/cm² (UV-X system; IROC Science AG, Zurich, Switzerland).

During ultraviolet A exposure, administration of the riboflavin-dextran solution was continued every 2 minutes. After surgery, antibiotic and corticosteroid drops were administered, a soft contact lens bandage was placed, and the eye was reexamined at the slit lamp. The contact lens was removed after the epithelial defect had closed. Antibiotics and corticosteroid drops were continued 4 times daily for 1 and 2 weeks, respectively. Patients were followed up for 12 months after surgery and underwent complete examinations at 1, 3, 6, and 12 months in predetermined windows of time (e.g., 3-month follow-up could occur from 11-14 weeks).

The sham control group received riboflavin 0.1% plus dextran ophthalmic solution alone. In this group, the epithelium was not removed. Riboflavin was administered topically every 2 minutes for 30 minutes. Next, the cornea was exposed to a sham treatment in which the ultraviolet A light was not turned on, during which time riboflavin was administered topically every 2 minutes for an additional 30 minutes. The sham control patients underwent complete examinations at 1 and 3 months in predetermined windows. Per the study protocol, the patient was allowed to cross over and receive full CXL treatment after the 3-month follow-up examination. Because all such patients had met the inclusion criteria for the study and anticipated ultimate treatment, the actual decision to cross over to treatment after the 3-month evaluation was made jointly by the patient and physician at that time. In

patients who met the study criteria in the fellow eye, the decision to proceed with fellow-eye treatment similarly was made after the 3-month follow-up.

Outcome Measures

Topography. Topography measurements were obtained using a rotating Scheimpflug camera (Pentacam HR; Oculus GmbH, Wetzlar, Germany). Topographic data were obtained before surgery and 1, 3, 6, and 12 months after surgery. For quantification of corneal curvature, maximum keratometry on the Scheimpflug system was analyzed. Maximum keratometry was chosen as the primary efficacy outcome because it measures a salient feature of keratoconus, that is, the steepness of keratoconic topographic distortion. Moreover, topographic maximum keratometry afforded an objective, quantitative end point and allowed the use of consistent hardware and software among the study sites. A difference of at least 1.0 D in the mean change in maximum keratometry from baseline to the 1-year follow-up when comparing the treatment and control groups was selected as a clinically meaningful outcome to define study success.

Visual Acuity and Refraction. The uncorrected distance visual acuity (UDVA), CDVA, and manifest refraction spherical equivalent (MRSE) were measured before surgery and after surgery at 1, 3, 6, and 12 months. Visual acuity measurements were obtained under controlled lighting conditions using a modified Lighthouse Early Treatment Diabetic Retinopathy Study visual acuity chart (second edition) with Sloan letters. Patients were tested 4 m from the visual acuity chart. If patients could not read any letters at 4 m, they were tested at 2 m. Visual acuity was recorded and analyzed as the number of Early Treatment Diabetic Retinopathy Study letters read in logarithm of the minimum angle of resolution (logMAR) units.⁶

Patient Questionnaire. All patients were asked to complete a questionnaire that scored various subjective vision function parameters. Outcomes of subjectively noted photophobia, difficulty driving at night, difficulty reading, diplopia, fluctuation in vision, glare, halo, starburst, dryness, pain, and foreign body sensation were assessed. The parameters were scored on a scale of 1 (none), 2 (mild), 3 (moderate), 4 (marked), or 5 (severe). The questionnaire was filled out before surgery and again 1 year after surgery. The data are presented as the mean subjective visual score for each of the 11 parameters queried.

Safety Analysis

A total of 293 eyes comprised the safety database and included eyes initially treated with CXL, eyes in the control group that crossed over to treatment, and fellow eyes that underwent CXL. Any adverse events were noted at each study visit and at any unscheduled visit. Endothelial cell count was obtained using specular microscopy (Konan Medical Inc, Irvine, CA) before surgery and 12 months after surgery. Three measurements were obtained, and the average cell count for each eye was used in the analysis.

Statistical Analysis

The study presented herein incorporates the pooled data of 2 individual clinical trials, accomplished among 11 study sites. Both trials were run concurrently, had identical inclusion and exclusion criteria, and followed identical procedural and follow-up protocols. Study treatments were begun in February 2008.

All safety and efficacy analyses were completed using the intent-to-treat population. All analyses are presented by treatment group. The intent-to-treat population consisted of all treated participants, analyzed according to randomized treatment.




Figure 1. Diagram showing study design. Patients were randomized to treatment versus sham control. CXL = corneal collagen crosslinking.

Randomization was generated by the sponsor and allocated to each study site in a numbered sequence of envelopes containing participant assignment. The randomization envelope was opened by the individual investigator just before patient treatment.

All efficacy analyses were performed by visit, and although P values are reported, the only ones that were used for statistical inference are the final analysis of month 12 data ($\alpha < 0.05$, 2-sided t test). The baseline score for all end points was defined as the preoperative measurement closest to the treatment date. For all efficacy analyses, only the randomized eyes were included; that is, efficacy analyses comprised 205 eyes of 205 patients and did not include crossover or fellow eye outcomes.

The primary efficacy end point was the difference between the CXL group and the control group for the mean change in maximum keratometry from baseline to month 12, with a 1.0-D or more difference between treatment and control groups hypothesized as a clinically significant difference. The primary end point data were summarized using descriptive statistics, and the differences in mean changes between the CXL treatment group and the control group at each time point were evaluated using a 2-sample t test to test the following hypothesis:

$$H_0: \mu_{CXL} - \mu_C = 0 \text{ versus } H_A: \mu_{CXL} - \mu_C \neq 0,$$

where H_0 is the null hypothesis and H_A is the statistical hypothesis for the primary efficacy end point, μ_C is the mean difference between the maximum keratometry value after baseline and the baseline maximum keratometry value for the control group, and μ_{CXL} is the mean difference between the maximum keratometry value after baseline and the baseline maximum keratometry value for the CXL group. A P value of 0.05 or less was considered statistically significant.

A last observation carried forward (LOCF) method was used to impute missing data for the 12-month analysis. Because the control group was eligible to receive treatment after the month 3 visit, those eyes that then underwent treatment were lost to follow-up. Therefore, in the LOCF analysis, efficacy data before crossover was carried forward to month 12, the study end point.

For all reported adverse events (AEs), the number of distinct treatment-emergent events and the number and percentage of participants who experienced the event were summarized by group and categorized by system organ class and preferred term using the *Medical Dictionary for Drug Regulatory Affairs* (version 14.1). The data are presented with events listed by preferred term in order of decreasing frequency in the treatment group. No formal statistical analysis was conducted on the AE data.

Results

Participant Baseline Demographics and Disposition

A total of 102 eyes were treated in the CXL treatment group and 103 eyes were in the sham control group. Of these, 90 eyes (87.4%) and 76 eyes (74.5%), respectively, remained in the study through the 12-month follow-up. Participant demographics are presented in [Table 1](#).

Postoperative Topography Changes after Corneal Collagen Crosslinking

Maximum Keratometry. In the CXL treatment group, there was a significant decrease in the mean maximum keratometry value (1.6 ± 4.2 D) between baseline and 12 months after surgery ($P < 0.001$). In the control group, there was a significant increase in the mean maximum keratometry value (1.0 ± 5.1 D) between baseline and 12 months after surgery ($P < 0.001$). The difference between maximum keratometry change between treatment and control was 2.6 D, a statistically significant finding ($P < 0.0001$). In treated eyes with maximum keratometry data at 1 year ($n = 89$), the maximum keratometry decreased by more than 2.00 D in 28 eyes (31%), remained within 2 D in 56 eyes (63%), and increased by 2.00 D or more in 5 eyes (6%; [Fig 2](#)). With regard to the time course of outcomes evolution in the CXL treatment group, mean maximum keratometry increased 1.5 D at month 1, decreased 1.8 D between months 1 and 3, and further decreased 0.7 D between months 3 and 6 and between months 6 and 12 ([Fig 3](#)). The keratometry data are summarized in [Table 2](#).

Visual Acuity

Corrected Distance Visual Acuity. [Table 3](#) shows the CDVA over time. In the CXL treatment group, there was a significant improvement of 5.7 letters of visual acuity between before surgery and 12 months after surgery. In the control group, there was a gain of approximately 2.2 letters. The difference in CDVA change at 1 year between the CXL treatment and control groups was 3.5 letters, a statistically significant finding ($P < 0.01$). In eyes with 12 months of follow-up CDVA data ($n = 83$), the CDVA improved by 10 letters or more in 23 eyes (28%), remained within 10 letters in 55 eyes (66%), and decreased 10 letters or more in 5 eyes (6%). One eye (1%) lost 15 letters or more of CDVA ([Fig 4](#)). Of the 5 eyes losing 10 letters or more, 2 had continued progression of maximum keratometry; in 1 eye that lost 11 letters, maximum keratometry increased from 57 to 60 D from baseline to 1 year; and in another eye that lost 14 letters, maximum keratometry increased from 66 to 74 D. No AE were reported in any of the 5 eyes losing 2 lines or more of CDVA. Over the course of the study, mean CDVA decreased by 0.4 letters at month 1 and increased by 4.4 letters between months 1 and 3, with further improvement of 0.9 letters between months 3 and 6 and 0.8 letters between months 6 and 12 ([Fig 5](#)).

Uncorrected Distance Visual Acuity. [Table 3](#) shows the UDVA over time. In the CXL treatment group, there was a significant improvement of approximately 4.4 letters of visual acuity between before surgery and 12 months after surgery. In the control group, there was a gain of approximately 2.6 letters. The difference in UDVA change at 1 year between the CXL treatment and control groups was 1.8 letters, a finding that was not statistically significant. In the treatment group, mean UDVA increased by 1.0 letters at month 1 and by 2.3 letters between months 1 and 3, with further improvement of 0.3 letters between months 3 and 6 and of 0.8 letters between months 6 and 12 ([Fig 5](#)).

Table 1. Preoperative Population Characteristics

	Corneal Collagen Crosslinking Group	Control Group	Total
Patients, no.	102	103	205
Age (yrs), mean \pm standard deviation	31.1 \pm 9.5	35.0 \pm 11.8	33.0 \pm 10.9
Gender (female/male), no. (%)	27/75 (26.5/73.5)	35/68 (34.0/66.0)	62/143 (30.2/69.8)
Maximum keratometry (diopters), mean \pm standard deviation	60.9 \pm 9.14	60.4 \pm 8.94	60.7

Refractive Changes

Table 4 shows the MRSE over time. In the CXL treatment group, there was a 0.1-D decrease in MRSE from before surgery to 12 months after surgery. In the control group, there was a decrease of 0.2 D from before surgery to 12 months after surgery. The difference in MRSE change at 1 year between the CXL treatment and control groups was not statistically significant.

Subjective Patient Questionnaire

All 11 parameters analyzed in the study showed improvement after 12 months in the CXL treatment group, with 6 reaching statistical significance. Figure 6 details the results of all preoperative and postoperative symptoms analyzed. Parameters found to be significantly improved from baseline to 1 year were night driving, difficulty reading, diplopia, glare, fluctuation in vision, and foreign body sensation.

Adverse Events

Table 5 lists all AEs that were reported at a rate of more than 5% throughout the study. Most of these were related to epithelial debridement at surgery and subsequent re-epithelialization. One severe ocular AE was reported. A 19-year-old received CXL after first being assigned to the control group. Ulcerative keratitis developed on postoperative day 3 and was treated with antimicrobials and resolved. At the 12-month examination, maximum keratometry had improved by 1 D, and CDVA and UDVA had decreased by 4 and 6 letters, respectively. At the final 12-month visit, AEs were reported in 5 eyes: persistent corneal haze in 2 eyes, corneal scar in 1 eye, endothelial folds in 1 eye, and irregular corneal epithelium in 1 eye. Clinical outcomes of the former 4 are presented below. The patient with irregular corneal epithelium first

manifested this sign at 5 days after the procedure and the finding was ongoing at 1 year. The event was graded as mild and the patient showed both a 4-D improvement in maximum keratometry and a 5-letter improvement in CDVA.

Corneal Haze

Corneal stromal haze, a demarcation line, or both were noted in 58 eyes (57%) at any examination throughout this study. At the 12-month follow-up, 2 eyes had retained stromal haze and 1 eye had a corneal scar. The first patient had mild haze at 1 year and showed a 2-D improvement in maximum keratometry, as well as improvements in CDVA and UDVA of 14 and 10 letters, respectively. The second patient had no change in maximum keratometry, a 10-letter decrease in CDVA, and a 4-letter improvement in UDVA. The third patient was reported to have a mild central scar, first noted at 17 days after CXL. He showed a 2-D improvement in maximum keratometry, but a 10-letter decrease in CDVA and no change in UDVA.

Endothelial Cell Analysis

Table 6 presents endothelial cell density analysis of the CXL treatment group and control group. There was no statistically significant difference in cell count change between the 2 groups. Over the course of 1 year, the treatment group had an average increase in endothelial cell density of 1%. Figure 7 shows the 1-year change in endothelial cell density stratified to individual mean gain or loss of cells. Of note, there were no reports of frank corneal edema. However, 1 reported eye had endothelial folds. In this eye, although endothelial cell count decreased from 2674 cells/mm² before surgery to 1529 cells/mm² after surgery, the cornea thinned from 506 to 391 μ m. Moreover, maximum keratometry

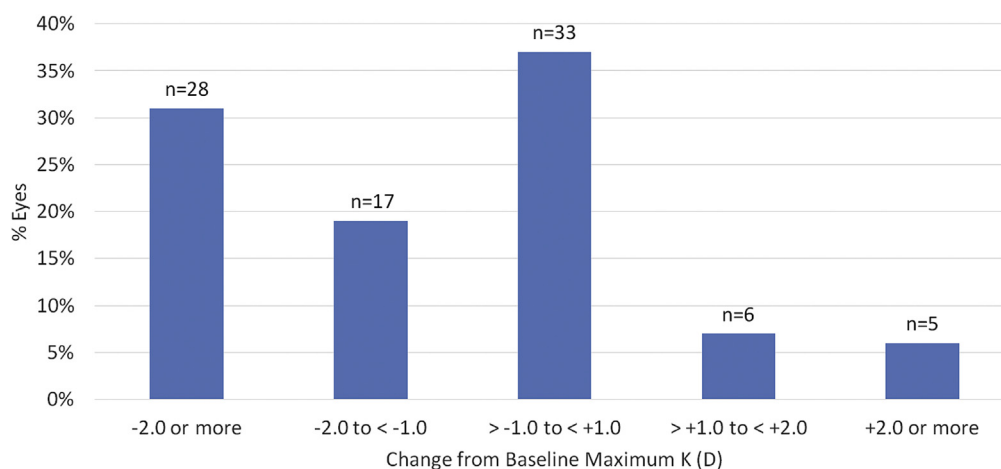


Figure 2. Bar graph showing the change in maximum keratometry (K) in individual eyes between baseline and 12 months after corneal collagen cross-linking. D = diopter.

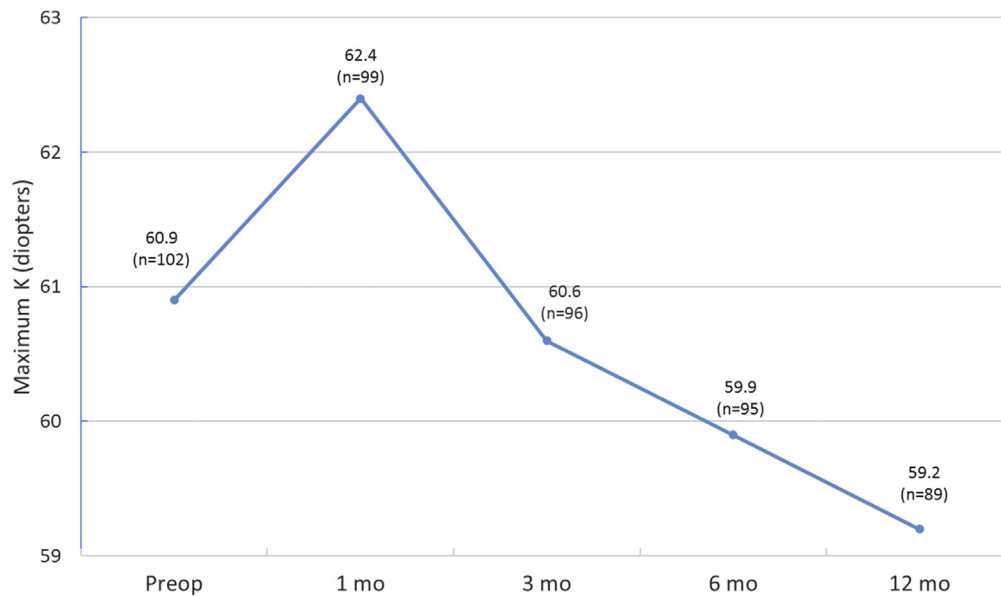


Figure 3. Graph showing the change in maximum keratometry (K) over time. mo = months; Preop = before surgery.

decreased from 65 to 59 D, UCVA improved from 19 to 34 letters, and CDVA improved from 19 to 47 letters.

Discussion

This article presents the outcomes of a United States multicenter, randomized, controlled clinical trial of CXL for the treatment of keratoconus. The essential goal of CXL is to decrease the progression of keratoconus. Heretofore, there has been no method available to stabilize the keratoconic cornea and achieve this goal. In this study, the steepening of the keratoconic cornea improved by 1.6 D 1 year after treatment compared with continued progression in the control group, suggesting that CXL would have a salutary effect on the disease’s prognosis. Based on these safety and efficacy outcomes, CXL was approved by the United States Food and Drug Administration for the treatment of progressive keratoconus in April 2016. Although the UV-X System was used as the ultraviolet light source in this study, Food and Drug Administration specifically

approved CXL using the KXL System. However, there is no notable difference in ultraviolet wavelength or energy delivered or in other attributes of the actual ultraviolet light between the systems.

Corneal collagen crosslinking is thought to strengthen the corneal stroma biomechanically and, consequently, to slow the progression of corneal ectatic diseases. In the CXL procedure, the photobiologic process depends on the interaction of riboflavin with ultraviolet A (365-nm) irradiation, with the formation of reactive species that interact with corneal proteins and lead to the formation of chemical bonds.^{7–11} In both in vitro and clinical studies of the cornea after CXL, a number of morphologic and physiologic changes have been reported.^{12–17} Indeed, studies show that, immediately after CXL, stress measurement increases in human corneas by more than 300%.¹⁸

By means of this corneal biomechanical strengthening, the essential clinical goal of CXL in keratoconus is to decrease disease progression over time. Because the severity of keratoconus generally is related to the degree of steepening and irregularity of the corneal optical architecture, the

Table 2. Postoperative Topographic Maximum Keratometry after Corneal Collagen Crosslinking

Group	Postoperative Maximum Keratometry (D)					P Value*
	Before Surgery	1 Month after Surgery	3 Months after Surgery	6 Months after Surgery	12 Months after Surgery	
CXL	60.9±9.2 (102)	62.4±9.1 (99)	60.6±8.8 (96)	59.9±8.3 (95)	59.2±8.3 (89)	<0.0001
CXL (LOCF model)	60.9±9.2 (102)	62.2±9.1 (102)	60.4±8.7 (102)	59.9±8.2 (102)	59.3±8.3 [†] (102)	
Control	60.4±8.9 (103)	59.2±12.6 (101)	61.0±10.6 (96)	62.6±10.9 (39)	62.1±0.8 (2)	
Control (LOCF model)	60.4±8.9 (103)	59.2±12.5 (103)	61.0±10.5 (103)	61.3±10.7 (103)	61.4±10.7 [†] (103)	

CXL = corneal collagen crosslinking; D = diopter; LOCF = last observation carried forward.

Data are mean ± standard deviation (number) unless otherwise indicated.

*t Test (2 sided; significance level, 0.05) for 12-month CXL vs. control (maximum keratometry change). Significant difference between treatment and control groups (LOCF analysis).

[†]Significant difference within group between preoperative and 1-year postoperative values.

Table 3. Postoperative Visual Acuity after Corneal Collagen Crosslinking

Group	Visual Acuity					P Value*
	Before Surgery	1 Month after Surgery	3 Months after Surgery	6 Months after Surgery	12 Months after Surgery	
CDVA						
CXL	33.2±13.4 (102)	32.8±13.0 (101)	37.9±11.6 (98)	38.7±11.8 (96)	39.4±11.7 (86)	<0.01
CXL (LOCF model)	33.2±13.4 (102)	32.8±12.9 (102)	37.2±12.1 (102)	38.1±12.1 (102)	38.9±11.8 [†] (102)	
Control	32.8±13.6 (103)	35.3±13.4 (99)	35.1±14.1 (98)	34.1±13.0 (37)	40.0±0.0 (2)	
Control (LOCF model)	32.8±13.6 (103)	35.3±13.2 (103)	35.3±13.9 (103)	35.0±13.8 (103)	35.0±13.8 (103)	
UDVA						
CXL	11.9±12.2 (102)	12.7±11.8 (99)	15.0±13.6 (98)	15.2±13.9 (96)	16.8±14.7 (89)	
CXL (LOCF model)	11.9±12.2 (102)	12.9±11.8 (102)	15.2±13.5 (102)	15.5±13.8 (102)	16.3±14.5 [†] (102)	
Control	8.2±11.0 (103)	10.2±12.4 (98)	10.3±12.2 (96)	7.9±12.3 (37)	4.0±0.80 (2)	
Control (LOCF model)	8.2±11.0 (103)	10.4±12.5 (103)	10.5±12.6 (103)	10.8±12.9 (103)	10.8±12.9 (103)	

CDVA = corrected distance visual acuity; CXL = corneal collagen crosslinking; LOCF = last observation carried forward; UDVA = uncorrected distance visual acuity.

Data are mean ± standard deviation (number) logarithm of the minimum angle of resolution Early Treatment Diabetic Retinopathy units unless otherwise indicated.

*t Test (2 sided; significance level, 0.05) for 12-month CXL vs. control (CDVA). Significant difference between treatment and control groups (LOCF analysis).

[†]Significant difference within group between preoperative and 1-year postoperative values.

primary efficacy outcome for this study was based on maximum keratometry, as measured by a Scheimpflug corneal topography system. Although not measuring all aspects of keratoconus severity, the topographic maximum keratometry reflects the severity of the keratoconic cone and affords an objective, quantitative end point for analysis that can be standardized among multiple study sites. Therefore, the change in maximum keratometry over time serves as a quantitative indicator of a change in keratoconus severity. A difference of at least 1.0 D in the mean change in maximum keratometry from baseline to 1 year, comparing the treatment and control groups, was chosen as a clinically meaningful end point of study success. Thus, either stabilization or improvement in maximum keratometry would indicate a positive effect of the procedure on disease evolution,

whereas an increase in maximum keratometry would suggest continued progression.

Topography Changes after Corneal Collagen Crosslinking

The mean maximum keratometry value of the CXL treatment group decreased by 1.6 D at 1 year, compared with 1.0 D of steepening in the control group, a difference of 2.6 D between treatment and control groups. Thus, our study demonstrates that CXL has a beneficial effect on corneal topography in keratoconus patients over the course of 1 year. This salient finding is in agreement with a number of international clinical trials using a similar protocol, which found decreases in maximum keratometry value of 2.01,³ 1.90,¹⁹ 1.46,²⁰ and

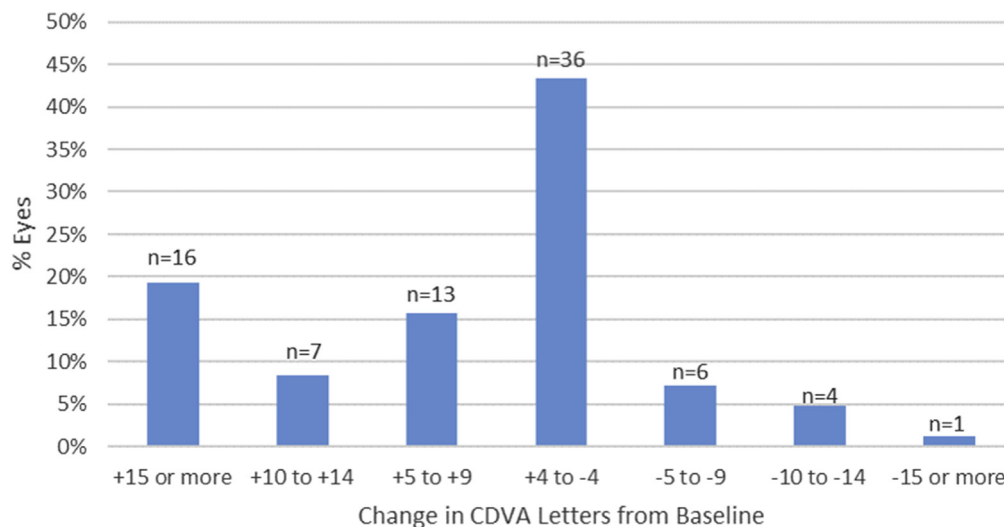


Figure 4. Bar graph showing the change in corrected distance visual acuity (CDVA; letters read) in individual eyes between baseline and 12 months after corneal collagen crosslinking.

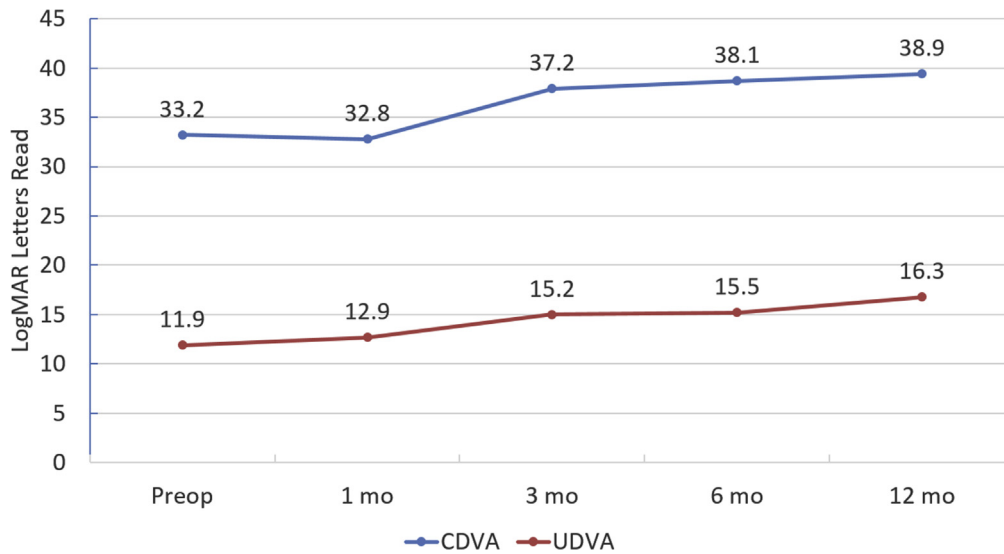


Figure 5. Graph showing the change in corrected distance visual acuity (CDVA) and uncorrected distance visual acuity (UCVA) over time. logMAR = logarithm of the minimal angle of resolution; mo = months; Preop = before surgery.

1.42 D²¹ after CXL. In addition to improved maximum keratometry, other topography and wavefront analyses of a single-center cohort of patients by one of the authors (P.S.H.) demonstrate a more general optical improvement after CXL, finding that quantitative descriptors of corneal topography,²² as well as both corneal and total ocular aberrations,²³ improve 1 year after CXL.

In addition to the standard metric of mean change in maximum keratometry, it is perhaps clinically clearer to the patient if we present results as proportions of patients with different outcomes; this may elucidate the patient’s understanding and better define procedure expectations. Therefore, it is helpful to look at the likelihood that an individual patient will substantially improve or decline. In our study, the maximum keratometry value decreased by 2.0 D or more in 28 eyes (32%) and increased by 2.0 D or more in 5 eyes (6%) 1 year after CXL. Although these latter 5 eyes may be considered treatment failures because cone progression was not stabilized,²⁴ it is unclear what the natural evolution of the disease otherwise might have manifested; it is possible that disease progression was slowed but not completely stopped, or indeed that progression proceeded apace. In an effort to define preoperative characteristics that may influence outcomes, additional reports from one author

(P.S.H.) suggest that eyes with steeper corneas before surgery,²⁵ as well as corneas with more central cones,²⁶ have a greater likelihood of topography improvement 1 year after surgery. The only independent predictor of improvement in maximum keratometry after CXL was preoperative maximum keratometry; eyes with a maximum keratometry of 55 D or more were 5.4 times more likely to have topographic flattening of 2.0 D or more after CXL compared with eyes with flatter corneas; however, there were no independent predictors of failure of the procedure to stabilize the cornea.²⁵

Vision Changes after Corneal Collagen Crosslinking

In addition to the primary efficacy measurement of maximum keratometry, changes in CDVA may point to additional benefits or, conversely, to safety concerns after CXL. Because decrease in vision in keratoconus results from a distorted corneal optical architecture, topography improvement would be expected to yield improved visual function. Indeed, in this study, CXL was associated with an improvement of more than 1 line of mean CDVA 1 year after surgery. Although this finding was statistically

Table 4. Postoperative Manifest Refraction Spherical Equivalent after Corneal Collagen Crosslinking

Group	Manifest Refraction Spherical Equivalent (D)				
	Before Surgery	1 Month after Surgery	3 Months after Surgery	6 Months after Surgery	12 Months after Surgery
CXL	-4.0±4.3 (102)	-4.1±4.5 (100)	-3.9±4.4 (98)	-4.1±4.4 (95)	-3.9±4.5 (90)
CXL (LOCF model)	-4.0±4.3 (102)	-4.2±4.5 (102)	-3.8±4.3 (102)	-3.9±4.3 (102)	-3.9±4.6 (102)
Control	-4.9±5.2 (103)	-4.9±4.9 (101)	-4.7±4.9 (98)	-4.8±5.0 (39)	-2.0±0.0 (2)
Control (LOCF model)	-5.0±5.2 (103)	-4.8±4.9 (103)	-4.8±5.0 (103)	-4.8±4.9 (103)	-4.8±4.9 (103)

CXL = corneal collagen crosslinking; D = diopter; LOCF = last observation carried forward. Data are mean ± standard deviation (number of patients).

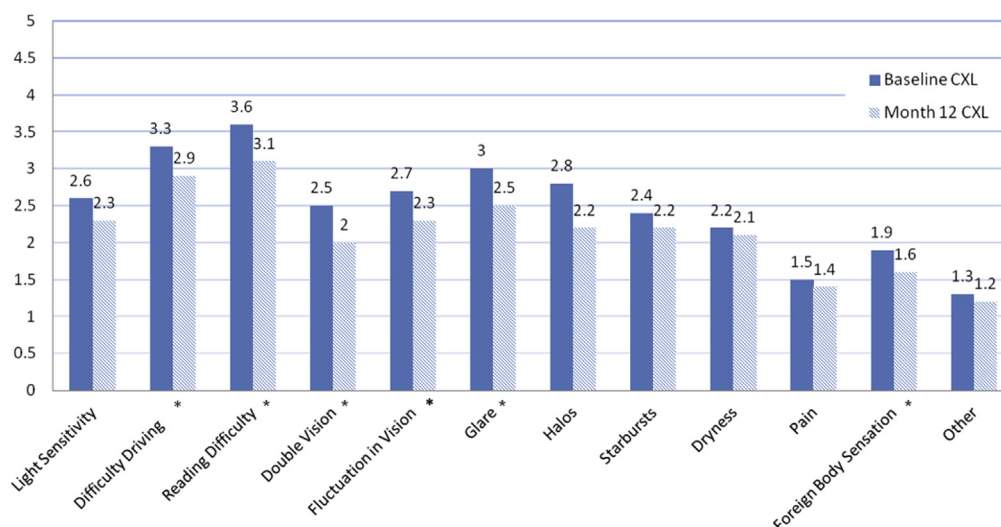


Figure 6. Bar graph showing the mean rating of subjective visual parameters before and 12 months after corneal collagen crosslinking (CXL) on a scale of 1 through 5. *P < 0.05 (statistical significance).

significant, the actual clinical significance is demonstrated better in studying the outcomes on an individual basis; among patients undergoing CXL, 23 eyes (24%) gained 2 lines or more of CDVA, whereas 5 eyes (6%) lost 2 lines or more. Thus, nearly one quarter of patients enjoyed a clinically meaningful increase in CDVA as a result of CXL, whereas some eyes did continue to progress. Our findings are in agreement with those of Vinciguerra et al,²⁷ who found that mean CDVA improved between 1 and 2 logMAR lines at 12 months after surgery. Similarly, at 1-year follow-up, Caporossi et al²⁸ and Raiskup-Wolf et al²⁰ found improvements in CDVA, noting continued improvement even after 1 year.

With regard to those 5 eyes in our study that lost 2 lines or more of CDVA, 2 showed continued topography progression, 2 showed residual corneal haze or scar, and 1 showed no potentially contributing cause. In the aforementioned multifactorial analysis,²⁵ the only independent predictor of a change in postoperative CDVA after CXL was the preoperative CDVA; those eyes with worse

preoperative CDVA ($\leq 20/40$) were 5.9 times more likely to experience an improvement in vision 1 year after CXL. However, with regard to eyes that lost vision after the procedure, the most salient indicator of an unwanted outcome, there were no independent preoperative predictors.

Analysis of UDVA showed slightly less than 1 line average of improvement in our study. This improvement is somewhat less than previously reported. Vinciguerra et al²⁷ reported a significant improvement in mean UDVA, from 0.77 logMAR before surgery to 0.57 logMAR 1 year after surgery. Similarly, Caporossi et al²⁹ reported a significant improvement in mean UDVA of 2.41 Snellen lines. In addition to these visual acuity improvements, it is notable that many patients noted a subjective improvement in a number of measures of their visual function after the CXL procedure³⁰ (Fig 6). Although we did find statistical significance for these subjective improvements, their actual clinical impact remains unclear.

Clinical Time Course after Corneal Collagen Crosslinking

It is important clinically for the ophthalmologist to understand the tempo of healing and outcomes evolution after CXL, both to identify untoward effects and to counsel the patient properly in terms of expectations. Topography and vision outcomes seem to follow a reproducible time course after treatment.³¹ Looking at the changes over time in the CXL treatment group, there was a worsening in maximum keratometry at 1 month, with improvement thereafter, continuing over 1 year (Fig 3). The time course of CDVA change was similar, with a slight drop at 1 month, followed by improvement (Fig 5).

This clinical time course after CXL reflects that of the natural history of CXL-associated stromal haze (discussed below) and corneal thickness measurements,³² suggesting that wound-healing responses continue over months concomitant with the evolution in clinical outcomes. Both

Table 5. Ocular Adverse Events in More Than 5% of Participants after Corneal Collagen Crosslinking

	Corneal Collagen Crosslinking Treatment Group (n = 102) (%)	Control Group (n = 103) (%)
Corneal opacity (haze)	57	4
Punctate keratitis	25	8
Corneal striae	24	12
Epithelial defect after 1 wk	23	1
Eye pain	17	3
Blurred vision	16	2
Photophobia	11	0
Conjunctival hyperemia	10	1
Ocular irritation	10	1
Decreased visual acuity	10	9
Dry eye	6	2
Increased lacrimation	5	0

Table 6. Endothelial Cell Density

Group	Baseline	3 Months after Surgery	Change from Baseline to 3 Months after Surgery	12 Months after Surgery	Change from Baseline to 12 Months after Surgery
CXL treatment (n = 66)	2622±370	2551±343	-72 (-2.7%)	2653±348	+31 (+1.2%)
Control (n = 86)	2575±410	2598±424	+24 (+0.9%)	Not obtained	Not obtained

CXL = corneal collagen crosslinking.
Data are mean cells/mm² ± standard deviation unless otherwise indicated.

epithelial and stromal healing and remodeling mechanisms may affect this time course of outcomes. The epithelium tends to mask the stromal cone of keratoconus.^{33,34} With corneal de-epithelialization in the CXL procedure, the more profound stromal irregularity is revealed, with an increase in measured maximum keratometry. As the epithelium heals and remodels over months, topographic improvement is seen. Stromal healing, too, may play a part in the time course after CXL. For instance, both in vitro and ex vivo studies have shown that CXL leads to an almost immediate loss of keratocytes in the corneal stroma, followed by repopulation over the next 6 months.^{13,35,36}

Safety of Corneal Collagen Crosslinking

Analyses of AEs in this study suggested an excellent safety profile for the CXL procedure. Corneal stromal haze was the most frequently reported AE in the study. Indeed, haze seems to be a normal concomitant of the CXL procedure. Typically, haze is observed first as dust-like change in the anterior corneal stroma that evolves into a mid-stromal demarcation line.³⁷ Corneal haze associated with CXL is most likely a result of back-scattered light, causing decreased corneal transparency, and likely demarcates the depth of the actual CXL effect.³⁸ Previous analysis of a single-center cohort by one of the authors (P.S.H.) found that CXL-associated haze peaks at 1 month, plateaus

between 1 and 3 months, clears between 3 and 6 months, and continues to return to baseline at 1 year; thus, this reflects the clinical time course of CXL outcomes.³⁹ Corroborating these results, in the current study, only 3 eyes continued to show stromal haze 1 year after surgery. To date, it remains unclear whether postoperative haze is an unwanted complication or a desired wound-healing effect demonstrating, and perhaps enhancing, the efficacy of the CXL procedure. Although 2 eyes in our study had a decrease of CDVA in the presence of ongoing haze, previous work has not shown a correlation of corneal haze with either topography or visual acuity outcomes.³⁹

Endothelial cell damage from CXL is a concern and could result from endothelial exposure to free radicals generated from the CXL process. The original parameters for CXL suggested a minimum stromal thickness of 400 µm to attenuate the ultraviolet A power and thus prevent endothelial damage.^{40,41} Indeed, in the study protocol, corneas needed to be swollen with a hypotonic riboflavin solution to the 400-µm threshold before proceeding with ultraviolet exposure.^{42,43} Results herein showed no damage to the corneal endothelium and no reports of corneal decompensation after CXL.

Microbial keratitis likely is one of the most severe potential complications of CXL. In this study, 1 reported corneal ulcer occurred in a patient initially assigned to the control group but subsequently underwent the CXL

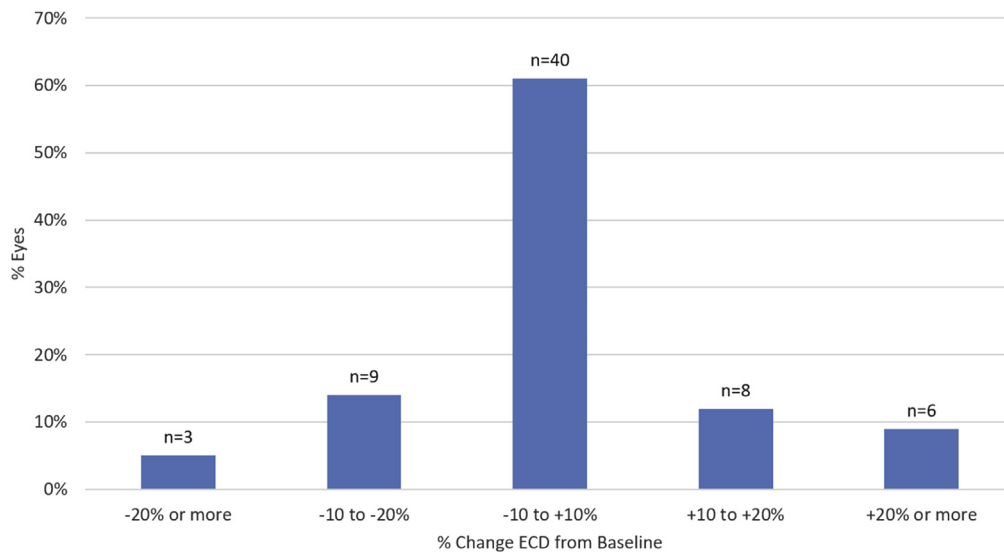


Figure 7. Bar graph showing the change in endothelial cell density (ECD) between baseline and 12 months after corneal collagen crosslinking.

procedure. Because a total of 293 eyes ultimately underwent CXL in this trial, the incidence was 0.3%. There have been several reports of microbial keratitis after CXL in the literature, including bacterial, fungal, acanthamoeba, and herpetic infections.⁴⁴ Given the epithelial defect and use of a therapeutic contact lens in the CXL procedure, care should be taken to ensure rapid re-epithelialization, to treat ocular surface pathologic features, and to maintain careful post-operative follow-up in order to detect early complications.⁴⁵

Study Limitations

Our study is limited by 2 attributes of the control group. First, eyes in the control group were allowed to cross over to treatment at 3 months. Thus, crossover eyes were lost to follow-up with regard to further control data; only 2 control eyes were available at 12 months. Because of this loss of data from crossover eyes, an LOCF analysis was used to impute missing data for 12-month analysis of the treatment versus control groups; in these analyses, data obtained before crossover were carried forward to follow-up windows in which actual data no longer could be obtained. In a study evaluating efficacy in decreasing the worsening of a progressive disease, the LOCF methodology seems valid for imputation. Keratoconus is a progressive condition without spontaneous remission or improvement. Thus, untreated keratoconic eyes would be expected to progress or, at best, remain stable, according to the disease's natural history. In fact, given the typical course of untreated keratoconus, using an LOCF model to compare treatment and control groups would be expected to be a conservative methodology to compare the efficacy of CXL treatment with the treatment of a control group. The LOCF model should bias the analysis toward a negative outcome because the data would be imputed as no change going forward, whereas disease progression generally would be expected in the setting of progressive keratoconus. Moreover, the treatment group may be expected to continue to improve over time, as noted in a number of international studies. Notwithstanding the difference of 2.6 D between the treatment and control groups at 12 months, as found using the LOCF model, when looking at the treatment group alone, in which complete 1-year data are available, there was a 1.6-D average improvement in maximum keratometry. That improvement in the CXL-treated eyes in itself is statistically significant and clinically meaningful and meets the study's primary efficacy criterion. A second limitation of the control group is that the epithelium was not removed in these eyes. Rather, they received riboflavin alone and were placed under a ultraviolet A light platform that was turned off. Therefore, any contribution of de-epithelialization, rather than the ultraviolet A light treatment, to patient outcomes was not accounted for by this control group methodology.

In conclusion, this randomized controlled clinical trial demonstrated the efficacy and safety of CXL for the treatment of progressive keratoconus. In addition to decreasing disease progression, CXL also had beneficial visual and optical effects such as a decrease in corneal steepness and improvement in visual acuity and subjective

visual function in some patients. Although this trial assessed results over a 1-year period, international studies have reported good stability over 10 years.⁴⁶ Indeed, the beneficial clinical effect of CXL is highlighted by Sandvik et al,⁴⁷ who reported a more than a 50% decrease in the frequency of keratoplasty in keratoconus patients in Norway, comparing a period before CXL was available with a similar period after CXL became well established. Certainly, the topographic and visual results reported herein support the efficacy of CXL in the stabilization of this progressive corneal disorder.

References

1. Krachmer JH, Feder RS, Belin MW. Keratoconus and related noninflammatory corneal thinning disorders. *Surv Ophthalmol.* 1984;28:293-322.
2. Rabinowitz YS. Keratoconus. *Surv Ophthalmol.* 1998;42:297-319.
3. Wollensak G, Spoerl E, Seiler T. Riboflavin/ultraviolet-A-induced collagen crosslinking for the treatment of keratoconus. *Am J Ophthalmol.* 2003;135:620-627.
4. Cartwright NEK, Tyrer JR, Marshall J. Age-related differences in the elasticity of the human cornea. *Invest Ophthalmol Vis Sci.* 2011;52:4324-4329.
5. National Institutes of Health Clinical Trials. Corneal collagen cross-linking for progressive keratoconus (CXL). NCT00647699. [http://www.clinicaltrials.gov/ct2/show/NCT00647699?term=NCT00647699&rank=1U.S.](http://www.clinicaltrials.gov/ct2/show/NCT00647699?term=NCT00647699&rank=1U.S;); Accessed December 2, 2008.
6. Holladay JT, Prager TC. Mean visual acuity [letter]. *Am J Ophthalmol.* 1991;111:372-374.
7. Hersh PS, Lytle GE, Friedman MD. Getting double crossed. *J Pediatr Ophthalmol Strabismus.* 2016;53:8-9.
8. Meek KM, Tuft SJ, Huang Y, et al. Changes in collagen orientation and distribution in keratoconus corneas. *Invest Ophthalmol Vis Sci.* 2005;46:1948-1956.
9. Kamaev P, Friedman MD, Sherr E, Muller D. Photochemical kinetics of corneal cross-linking with riboflavin. *Invest Ophthalmol Vis Sci.* 2012;53:2360-2367.
10. Kamaev P, Smirnov M, Friedman MD, et al. Photochemical kinetics model of corneal cross-linking with riboflavin. *Invest Ophthalmol Vis Sci.* 2015;56:3004.
11. Hayes S, Kamma-Lorger CS, Boote C, et al. The effect of riboflavin/UVA collagen cross-linking therapy on the structure and hydrodynamic behaviour of the ungulate and rabbit corneal stroma. *PLoS One.* 2013;8:52860.
12. Wollensak G, Wilsch M, Spoerl E, Seiler T. Collagen fiber diameter in the rabbit cornea after collagen crosslinking by riboflavin/UVA. *Cornea.* 2004;23:503-507.
13. Wollensak G, Spoerl E, Wilsch M, Seiler T. Keratocyte apoptosis after corneal collagen cross-linking using riboflavin/UVA treatment. *Cornea.* 2004;23:43-49.
14. Spoerl E, Wollensak G, Dittert DD, Seiler T. Thermo-mechanical behavior of collagen-cross-linked porcine cornea. *Ophthalmologica.* 2004;218:136-140.
15. Dohlman CH, Hedbys BO, Mishima S. The swelling pressure of the corneal stroma. *Invest Ophthalmol.* 1962;1:158-162.
16. Spoerl E, Wollensak G, Seiler T. Increased resistance of crosslinked cornea against enzymatic digestion. *Curr Eye Res.* 2004;29:35-40.
17. Wollensak G, Iomdina E. Long-term biomechanical properties of rabbit cornea after photodynamic collagen crosslinking. *Acta Ophthalmol.* 2009;87:48-51.

18. Wollensak G, Spoerl E, Seiler T. Stress-strain measurements of human and porcine corneas after riboflavin-ultraviolet-A-induced cross-linking. *J Cataract Refract Surg.* 2003;29:1780-1785.
19. Caporossi A, Mazzotta C, Baiocchi S, Caporossi T. Long-term results of riboflavin ultraviolet A corneal collagen cross-linking for keratoconus in Italy: the Siena Eye Cross Study. *Am J Ophthalmol.* 2010;149:585-593.
20. Raiskup-Wolf F, Hoyer A, Spoerl E, Pillunat LE. Collagen crosslinking with riboflavin and ultraviolet-A light in keratoconus: long-term results. *J Cataract Refract Surg.* 2008;34:796-801.
21. Grewal DS, Brar GS, Jain R, et al. Corneal collagen cross-linking using riboflavin and ultraviolet-A light for keratoconus; one-year analysis using Scheimpflug imaging. *J Cataract Refract Surg.* 2009;35:425-432.
22. Greenstein SA, Fry KL, Hersh PS. Corneal topography indices after corneal collagen crosslinking for keratoconus and corneal ectasia: one year results. *J Cataract Refract Surg.* 2011;37:1282-1290.
23. Greenstein SA, Fry KL, Hersh MJ, Hersh PS. Higher-order aberrations after corneal collagen crosslinking for keratoconus and corneal ectasia. *J Cat Refract Surg.* 2012;38:292-302.
24. Koller T, Mrochen M, Seiler T. Complication and failure rates after corneal crosslinking. *J Cataract Refract Surg.* 2009;35:1358-1362.
25. Greenstein SA, Hersh PS. Characteristics influencing outcomes of corneal collagen crosslinking for keratoconus and ectasia: implications for patient selection. *J Cataract Refract Surg.* 2013;39:1133-1140.
26. Greenstein SA, Fry KL, Hersh PS. Effect of topographic cone location on outcomes of corneal collagen crosslinking for keratoconus and corneal ectasia. *J Refract Surg.* 2012;28:397-405.
27. Vinciguerra P, Albè E, Trazza S, et al. Refractive, topographic, tomographic, and aberrometric analysis of keratoconic eyes undergoing corneal cross-linking. *Ophthalmology.* 2009;116:369-378.
28. Caporossi A, Mazzotta C, Baiocchi S, Caporossi T. Long-term results of riboflavin ultraviolet A corneal collagen cross-linking for keratoconus in Italy: the Siena Eye Cross Study. *Am J Ophthalmol.* 2010;149:585-593.
29. Caporossi A, Baiocchi S, Mazzotta C, et al. Parasurgical therapy for keratoconus by riboflavin-ultraviolet type A rays induced crosslinking of corneal collagen; preliminary results in an Italian study. *J Cataract Refract Surg.* 2006;32:837-845.
30. Brooks NO, Greenstein SA, Fry KL, Hersh PS. Patient subjective visual function after corneal collagen crosslinking for keratoconus and corneal ectasia. *J Cataract Refract Surg.* 2012;38:615-619.
31. Hersh PS, Greenstein SA, Fry KL. Corneal collagen cross-linking for keratoconus and corneal ectasia. *J Cataract Refract Surg.* 2011;37:149-160.
32. Greenstein SA, Shah VP, Fry KL, Hersh PS. Corneal thickness changes after corneal collagen crosslinking for keratoconus and corneal ectasia. *J Cataract Refract Surg.* 2011;37:691-700.
33. Reinstein DZ, Gobbe M, Archer TA, et al. Epithelial, stromal, and total corneal thickness in keratoconus: three dimensional display with Artemix very-high frequency digital ultrasound. *J Refract Surg.* 2010;26:259-271.
34. Maia Rocha K, Straziota CP, Stulting RD, Randelman JB. Spectral-domain OCT analysis of regional epithelial thickness profiles in keratoconus, postoperative corneal ectasia, and normal eyes. *J Refract Surg.* 2013;29:173-179.
35. Gefen A, Shalom R, Elad D, Mandel Y. Biomechanical analysis of the keratoconic cornea. *J Mech Behav Biomed Mater.* 2009;2:224-236.
36. Mazzotta C, Traversi C, Baiocchi S, et al. Corneal healing after riboflavin ultraviolet-A collagen crosslinking determined by confocal laser scanning microscopy in vivo: early and late modifications. *Am J Ophthalmol.* 2008;146:527-533.
37. Seiler T, Hafezi F. Corneal cross-linking-induced stromal demarcation line. *Cornea.* 2006;25:1057-1059.
38. Mazzotta C, Balestrazzi A, Baiocchi S, et al. Stromal haze after combined riboflavin-UVA corneal collagen cross-linking in keratoconus: in vivo confocal microscopic evaluation. *Clin Exp Ophthalmol.* 2007;35:580-582.
39. Greenstein SA, Fry KL, Bhatt J, Hersh PS. The natural history of stromal haze after corneal collagen crosslinking for keratoconus and corneal ectasia. *J Cataract Refract Surg.* 2010;35:2105-2114.
40. Wollensak G, Spoerl E, Reber F, et al. Corneal endothelial cytotoxicity of riboflavin/UVA treatment in vitro. *Ophthalmic Res.* 2003;35:324-328.
41. Spoerl E, Mrochen M, Sliney D, et al. Safety of UVA-riboflavin cross-linking of the cornea. *Cornea.* 2007;26:385-389.
42. Rosenblat E, Hersh PS. Intraoperative corneal thickness change and clinical outcomes after corneal collagen cross-linking. *J Cataract Refract Surg.* 2016;42:596-605.
43. Hafezi F, Mrochen M, Iseli HP, Seiler T. Collagen cross-linking with ultraviolet-A and hypotonic riboflavin solution in thin corneas. *J Cataract Refract Surg.* 2009;35:621-624.
44. Sharma N, Maharna P, Singh G, Titival J. Pseudomonas keratitis after collagen crosslinking for keratoconus: case report and review of literature. *J Cataract Refract Surg.* 2010;36:517-520.
45. Lesniak SP, Hersh PS. Transepithelial corneal collagen crosslinking for keratoconus. *J Cataract Refract Surg.* 2014;40:1971-1979.
46. Raiskup F, Theuring A, Pillunat LE, Spoerl E. Corneal collagen crosslinking with riboflavin and ultraviolet-A light in progressive keratoconus: ten-year results. *J Cataract Refract Surg.* 2015;41:41-46.
47. Sandvik GF, Thorsrud A, Raen M, et al. Does corneal collagen crosslinking reduce the need for keratoplasties in patients with keratoconus? *Cornea.* 2015;34:991-995.

Footnotes and Financial Disclosures

Originally received: November 23, 2016.

Final revision: March 29, 2017.

Accepted: March 29, 2017.

Available online: May 7, 2017.

Manuscript no. 2016-870.

¹ Cornea and Laser Eye Institute- Hersh Vision Group, CLEI Center for Keratoconus, Teaneck, New Jersey, and the Department of Ophthalmology, Rutgers Medical School, Newark, New Jersey.

² Stulting Research Center, Woolfson Eye Institute, Atlanta, Georgia.

³ Avedro, Inc., Waltham, Massachusetts.

⁴ Durrie Vision, Overland Park, Kansas.

⁵ See Clearly Vision Group, McLean, Virginia.

*U.S. Crosslinking Study Group: Perry S. Binder, MD, Gordon, Binder & Weiss Vision Institute, CA; Eric D. Donnenfeld, MD, Ophthalmic Consultants of Long Island, New York; Daniel Durrie, MD, Durrie Vision, Overland Park, KS; David Hardten, MD, FACS, Minnesota Eye Consultants, Minneapolis, MN; Peter Hersh, MD, Cornea and Laser Eye Institute,

Teaneck, NJ; Francis Price, Jr., MD, Price Vision Group, Indianapolis, IN; J. Bradley Randleman, MD, Emory Vision, Atlanta, GA; David Schanzlin, MD, UCSD Shiley Eye Center, San Diego, CA; Walter Stark, MD, Wilmer Eye Institute, Baltimore, MD; R. Doyle Stulting, MD, PhD, Emory Vision, Atlanta, GA; William Trattler, MD, Center for Excellence in Eye Care, Miami, FL; Steven Trokel, MD, Columbia University, New York, NY.

Financial Disclosure(s):

The author(s) have made the following disclosure(s): P.S.H.: Consultant – Avedro, Inc. (Waltham, MA)

R.D.S.: Consultant – Peschke Meditrade, Alcon Laboratories, Calhoun Vision, Cambium Medical Technologies, EyeYon, Hydrolenz, Ophtec, Promisight, TearLab; Financial support – Peschke Meditrade, Intelon, TearLab; Equity owner – Cambium Medical Technologies, CXL Ophthalmics, Ocumetrics, TearLab; Lecturer – Avedro, Inc. (Waltham MA); Equipment – Intelon

D.M.: Former employee – Avedro, Inc. (Waltham MA)

D.S.D.: Consultant and equity owner – Avedro, Inc. (Waltham, MA)

R.K.R.: Employee and equity owner – Avedro, Inc. (Waltham, MA); Patents – Avedro, Inc.

The data reported in this article were derived from the clinical trials carried out for United States Food and Drug Administration premarket approval and were funded by Avedro, Inc., Waltham, Massachusetts.

Author Contributions:

Conception and design: Hersh, Stulting

Analysis and interpretation: Hersh, Stulting, Muller, Durrie, Rajpal

Data collection: Hersh, Stulting, Durrie

Obtained funding: Muller

Overall responsibility: Hersh

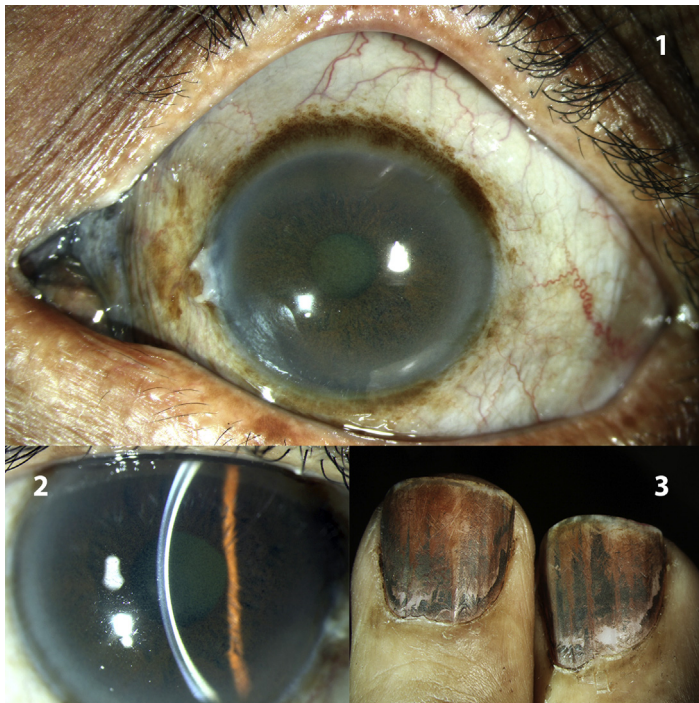
Abbreviations and Acronyms:

AE = adverse event; **CDVA** = corrected distance visual acuity; **CXL** = corneal collagen crosslinking; **D** = diopter; **LOCF** = last observation carried forward; **logMAR** = logarithm of the minimum angle of resolution; **MRSE** = manifest refraction spherical equivalent; **UDVA** = uncorrected distance visual acuity.

Correspondence:

Peter S. Hersh, MD, Cornea and Laser Eye Institute – Hersh Vision Group, CLEI Center for Keratoconus, 300 Frank W. Burr Boulevard, Suite 71, Teaneck, NJ 07666. E-mail: phersh@vision-institute.com.

Pictures & Perspectives



Argyrosis

A 65-year-old silversmith presented with a bluish-grey discoloration of the caruncle, conjunctiva (Fig 1), and posterior corneal stroma (Fig 2) in both eyes. Greyish discoloration of the finger nails (Fig 3) was noted as well. Argyrosis refers to the pigmentation of the conjunctiva, cornea, skin, and external mucosal membranes with silver from chronic occupational exposure or topical silver-containing medicines (Magnified version of Figs 1-3 available online at www.aaojournal.org).

ARUN KUMAR PANIGRAHI, MD
LOKESHWARI ARULJOTHI, MD
VENKATESH N. PRAJNA, MD

Department of Cornea and Refractive Services, Aravind Eye Care System, Madurai, India